

Ceramic implant vs endodontic treatment

Dr Dr Johann Lechner, PhD, Germany

Introduction

Where are the evaluation criteria to determine the success of endodontic treatment? Why are there no additional tools to determine local painlessness versus a systemic toxicity focused approach? How can patients be convinced to get their root fillings replaced with immediate ceramic implants? In the following, scientific based arguments will be given from an author having 16 years of experience in ceramic implants. His scientific based publications are being released in international PubMed indexed medical journals and the research on this topic was published in the International Journal of General Medicine ("Stimulation of proinflammatory cytokines by volatile sulfur compounds in endodontically-treated teeth", Lechner, von Baehr).

New methods to reduce risks

Researchers in the field of modern dental endodontics are well aware of the problem of bacterial colonization in the tubules of root-filled teeth (RFT), and new methods for reducing these risks are constantly being developed. A control X-ray image is standard practice and considered to be the only method used for the diagnostic assessment of RFT. However, X-ray scans are insufficient, since chemically defined toxins cannot be visually identified. Even though X-rays of root canal treatment do not show anomalies, these areas often contain bacteria as

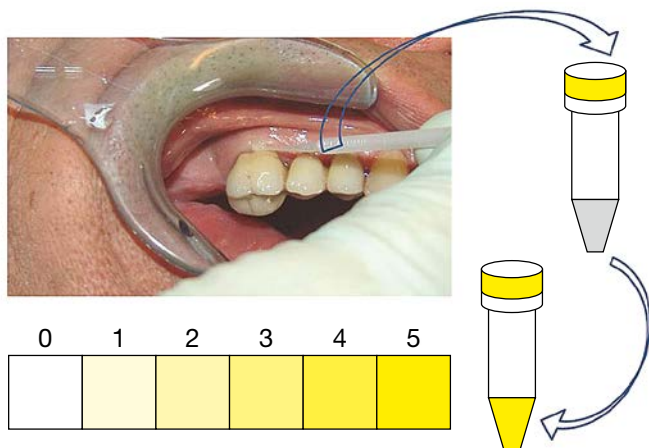


Fig. 1: The semi-quantitative chairside test; color change indicates higher concentration of sulfhydryls.

well as inflamed or necrotic tissue, which proves that not all periradicular inflammations can be diagnosed with the help of X-rays¹. Anaerobes are sulfate-reducing bacteria and are most frequently isolated from primarily and secondarily infected root canals. Persistent microorganisms in endodontically-treated teeth are the main producers of methyl mercaptan, dimethyl sulfide and diethyl sulfide (Merc/Thio)². In the past, there was no process available to reliably identify RFT, using the suspected outgas of Merc/Thio produced by bacterial degradation products and biogenic amines in the form of volatile sulfur compounds (VSC). Thus, we expanded our investigation to develop an additional evaluation criterion in order to semiquantitatively determine the presence of VSC, using a volatile sulfur hydrogen compound indicator (VSHCI).

The chairside test

Hydrogen sulfide can be displayed by utilizing the chairside test called OroTox[®]. The procedure is painless and simple to perform: A nonsterile paper tip – or alternatively, a small sponge, is inserted into the sulcus of the suspected tooth. After one minute it is removed and the sample from the sulcus fluid is inserted into the volatile compound reagent container. After five minutes, the staining of the reagent is examined: The more hydrogen sulfide compounds are present in the sample, the more the indicator liquid turns yellow. The VSCI detects the elevated discharge of bacterial toxins in the sulcus of the suspected teeth, based on six gradings (0 = zero; 1 = moderate; 2 = evident; 3 = clear; 4 = strong; and 5 = extremely strong). The degree of coloration of the reagent may be used to semiquantitatively determine the amount of toxin that can be resorbed in the sulcus (Fig. 1).

The chairside test helps dentists to decide whether RFT should be viewed as critical for a patient with immunological diseases, due to a high Merc/Thio content⁴, even if X-rays of the root tip do not indicate signs of change. We have evaluated the ex vivo immune response of peripheral blood mononuclear cells (PBMC) to VSC in 354 patients with systemic diseases. The findings correlate with semi-quantitative values of a volatile sulfur compound indicator (VSCI) applied directly to the RFT. Our data elucidate the role of VSC in patients with immunologic diseases and

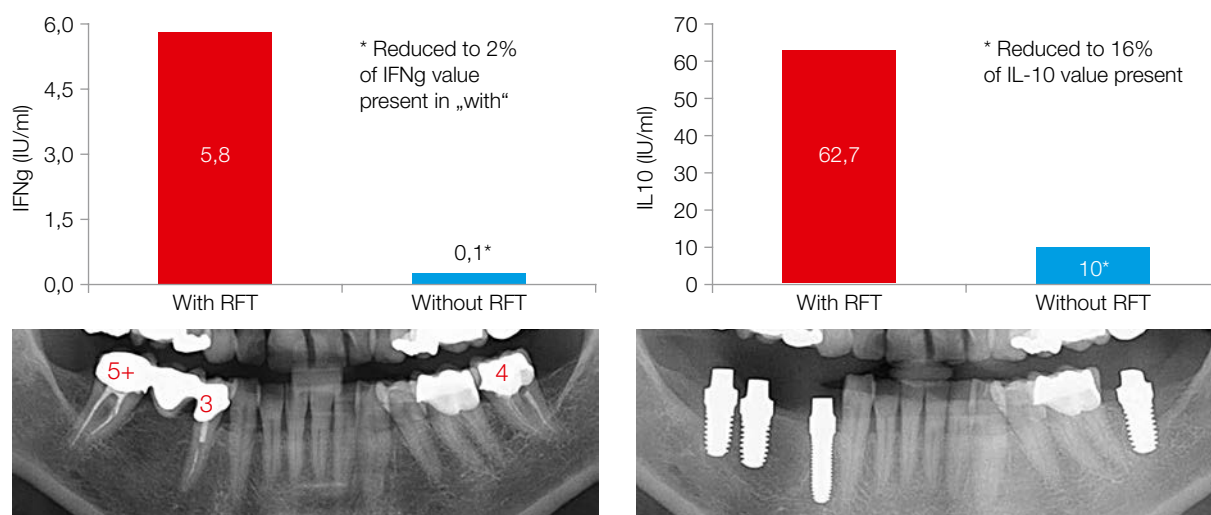


Fig. 2: An example of a clinical sample tested for IFNg and IL-10 sensitization to Merc/Thio exposure before and after the removal of RFT.

the role of the chair side test OroTox® in correlation to IFNg and IL-10 sensitization in PBMC. The connection between ex vivo-stimulated cytokines and endodontically-derived sulfur components is supported by the fact that the number of interferon gamma and/or interleukin-10 positive sensitized patients declined significantly three to eight months after the extraction of the corresponding teeth. Figure 2 shows a patient with dramatically lowered levels of IFNg and IL-10, after the exchange of RFT with high levels of VSC, with regard to the OroTox® test.

Identifying disease correlations

Scientific research finds that diabetes correlates significantly with a higher prevalence of periapical radiolucencies in endodontically treated teeth.⁵ In contrast, critics of root canals believe that they may contribute to immunological diseases and consider X-ray imaging to be insufficient for the purpose of determining possible systemic effects of toxins that derive from root fillings. Apical periodontitis (AP) is a chronic inflammatory disorder of the periradicular tissues caused by bacterial invasion at the apex of the tooth root.⁶ There are epidemiologic studies proving the correlation between AP and various diseases. For example, AP is associated with increased rates of myocardial infarction (with acute coronary syndromes occurring 2.7 times more frequently in patients with such infections⁷), as well as clinical depression, increasingly severe depression and a reduced quality of life.⁸ Moreover, AP is also associated with an increase in the translocation of gram-negative bacteria.⁹⁻¹⁰ A study on a total of 248 patients with acute myocardial infarction as well as 249 healthy controls underlines that patients, who have experienced a myocardial infarction, had a higher risk of developing inflammatory processes – especially of endodontic origin – than healthy patients.¹¹ Patients presenting lesions of endodontic origin or pulpal inflammation had an increased risk of developing a coronary heart disease.¹² Bacterial DNA that is typical for an endodontic infection, mainly oral viridans streptococci, was measured in 78.2% of thrombi, and periodontal pathogens were measured in 34.7%. Dental infections and oral bacteria, especially viridans streptococci, are associated with the development of an acute coronary throm-

bosis. There is also a significant correlation between periodontitis and depression.¹³

However, there is no data showing a correlation between VSC levels in the root canals of patients with AP and systemic and immunological diseases. We presented a study, which is one of the first to statistically link a group of patients to multiple systemic and immunological diseases (SyD) with endotoxin levels originating from AP (DENTISTRY. Volume 8, Issue 3; "Impact of Endodontically Treated Teeth on Systemic Diseases"; Lechner, von Baehr). The study indicates there is a significant increase in root canal endotoxin levels in patients with AP, in comparison to healthy controls (HC) without AP. The comparison made between the HC and SyD groups provides the first indication of the possible connections between RFT and SyD. It indicates that endodontically treated and root-filled teeth may enhance immunological and systemic disturbances on the one hand and may be involved in the development of SyD on the other hand. Vice versa, the presence of SyD may influence, in some way, local inflammatory reactions such as AP. High local H₂S values with the reagent as well as a high frequency of immunosensitization to biogenic amines in patients with SyD amplify this correlation. With regard to the increasing prevalence of immune system diseases, widespread endodontic measures should be assessed more critically. For practitioners, the local measurement of VSC, using the OroTox® test, draws attention to the correlation between the outcome of endodontic treatment and systemic diseases. For more than 15 years, we offer ceramic implant replacements as an alternative to RFT in order to help successfully avoiding SyD in our patients.

contact

Dr Dr Johann Lechner, PhD

Head of Clinic for Integrative Dentistry
Grünwalder Straße 10A
81547 Munich, Germany
Tel.: +49 89 6970129
drlechner@aol.com
www.dr-lechner.de

References

Ceramic implant vs endodontic treatment

Dr Johann Lechner, PhD, Germany

ceramic implants: international magazine of ceramic implant technology, 2/18

1. Lin IM, Skribner JE, Gaengler P. Factors associated with endodontic treatment failures. *J Endod.* (1992); 18: 625-7.
2. Jung IY, Choi BK, Kum KY, Roh BD, Lee SJ, Lee CY, Park DS. Molecular epidemiology and association of putative pathogens in root canal infection. *J Endod* (2000); 26:599-604.
3. Lechner J. Mehrdimensionale Systemdiagnose des wurzelgefüllten Zahnes [Multi-dimensional system diagnosis of the root-filled tooth]. *ZWR-Das deutsche Zahnärzteblatt.* (2012); 121: 640-644.
4. Tansy MF, Kendall FM, Fantasia J, Landin WE, Oberly SR, Sherman W. Acute and subchronic toxicity studies of rats exposed to vapors of methyl mercaptan and other reduced-sulfur compounds. *J Toxicol Environ Health* (1981); 8:71-88.
5. Segura-Egea Jj, Martín-González J, Castellanos-Cosano L. Endodontic medicine: connections between apical periodontitis and systemic diseases. *Int Endod J* 2015;48:933–951.
6. Nair PNR (2006) On the causes of persistent apical periodontitis: a review. *Int Endod J* 39(4):249–281.
7. Curvers D, Fieuws F. Prevalence of apical periodontitis and root filled teeth in a Belgian subpopulation found on CBCT images. *International Endodontic Journal* · March 2016. DOI: 10.1111/iej.12631.
8. Gomes C, et al. Increased Root Canal Endotoxin Levels are Associated with Chronic Apical Periodontitis, Increased Oxidative and Nitrosative Stress, Major Depression, Severity of Depression, and a Lowered Quality of Life. *Mol. Neurobiol.* 2017 DOI 10.1007/s12035-017-0545-z.
9. Berk M, Williams LJ, Jacka FN, O'Neil A, Pasco JA, Moylan S, Allen NB, Stuart AL, Hayley AC, Byne ML, Maes M (2013) So depression is an inflammatory disease, but where does the inflammation come from? *BMC Med* 11(1):1–16.
10. Herath TD, Darveau RP, Seneviratne CJ, Wang CY, Wang Y, Jin L (2016) Heterogeneous *Porphyromonas gingivalis* LPS modulates immuno-inflammatory response, antioxidant defense and cytoskeletal dynamics in human gingival fibroblasts. *Scientific Reports* 6:1– 15.
11. Willershausen I et al. Association between chronic periodontal and apical inflammation and acute myocardial infarction. *Odontology.* 2014 Jul;102(2):297-302.
12. Pasqualini D et al. Association among oral health, apical periodontitis, CD14 polymorphisms, and coronary heart disease in middle-aged adults. *J Endod.* 2012 Dec;38(12):1570-7.
13. Kumar A, Kardkal A, Debnath S, Lakshminarayan J (2015) Association of periodontal health indicators and major depressive disorder in hospital outpatients. *J Indian Soc Periodontol* 19(5): 507–511.